

## Effect of Flow Diversion Treatment on Very Small Ruptured Aneurysms

### Zsolt Kulcsár, MD

Department of Neuroradiology,  
Hirslanden Clinic,  
Zurich, Switzerland

### Stephan G. Wetzel, MD

Department of Neuroradiology,  
University Hospital of Basel,  
Basel, Switzerland

### Luca Augsburger, PhD

Laboratory of Hemodynamics and  
Cardiovascular Technology,  
Federal Institute of Technology,  
Lausanne, Switzerland

### Andreas Gruber, MD, PhD

Department of Neurosurgery,  
University of Vienna,  
Vienna, Austria

### Isabel Wanke, MD, PhD

Department of Neuroradiology,  
Hirslanden Clinic,  
Zurich, Switzerland; and  
Department of Neuroradiology,  
University of Essen,  
Essen, Germany

### Daniel Andre Rüfenacht, MD, PhD

Department of Neuroradiology,  
Hirslanden Clinic,  
Zurich, Switzerland

#### Reprint requests:

Zsolt Kulcsár, MD,  
Neuroradiologie, Klinik Hirslanden,  
Witellikerstrasse 40,  
8032, Zürich, Switzerland.  
E-mail: kulcsarszolt22@gmail.com

Received, July 28, 2009.

Accepted, January 20, 2010.

Copyright © 2010 by the  
Congress of Neurological Surgeons

**BACKGROUND:** Ruptured aneurysms of < 2 mm are not amenable to endovascular coiling and therefore pose a significant treatment challenge.

**OBJECTIVE:** To test recently introduced flow diverters that allow endovascular reconstruction via another method and may represent a new treatment option for such lesions.

**PATIENTS AND METHODS:** Three female patients presented with acute subarachnoid hemorrhage. An aneurysm of < 2 mm was identified in all patients as the cause of bleeding. The aneurysms were located at the C2 segment of the internal carotid in 2 patients and on the basilar bifurcation in the other. All patients had failed early endovascular treatment attempts. Flow diversion with the SILK flow diverter was offered as an alternative in each patient.

**RESULTS:** SILK deployment successfully eliminated the aneurysms in all 3 instances. One of the aneurysms was excluded from contrast material visualization immediately after stent deployment. Transient thrombotic complication was observed in the case of the basilar artery aneurysm. It resolved with the administration of intraarterial tirofiban. There was no treatment-related morbidity, and none of the aneurysms reruptured after SILK implantation during a clinical follow-up of at least 4 months (range, 4-10 months). Imaging follow-up showed complete vessel remodeling in all cases.

**CONCLUSION:** Flow diversion treatment prevented rebleeding during the follow-up period. Reverse remodeling of the concerned vascular segment with delayed disappearance of the aneurysm was observed in each case.

**KEY WORDS:** Cerebral aneurysm, Flow diversion, SILK, Subarachnoid hemorrhage, Uncoilable

Neurosurgery 00:000-000, 2010


DOI: 10.1227/01.NEU.0000372920.39101.55

www.neurosurgery-online.com

Subarachnoid hemorrhage (SAH) related to very small (< 2 mm) intradural aneurysms is not common and poses significant diagnostic and therapeutic challenges. These lesions may be blisterlike, dissecting, or saccular type. Endovascular treatment with coils is difficult and may pose significant technical problems in achieving endosaccular occlusion because there is a high risk that these lesions may be too small and fragile for safe catheterization and implant insertion. Parent vessel occlusion can be considered as an alternative if collateral pathways are sufficient. Stent redirection of blood flow in the parent vessel to allow aneurysm thrombosis and reverse remodeling of the wall might be an alternate and simpler treatment option.

**ABBREVIATIONS:** DSA, digital subtraction angiography; FD, flow diverter; SAH, subarachnoid hemorrhage

The structural design and high porosity of conventional stents may not be optimal to facilitate complete vascular reconstruction, although some have reported success.<sup>1</sup> With the advent of flow diverter (FD) implants, the technical ability to improve vascular remodeling became possible. These prostheses have a much finer mesh that evenly covers the orifice of the aneurysm regardless of its size. Such an FD device is the SILK (BALT Extrusion, Montmorency, France; Figure 1). This flexible, self-expanding device is specifically designed to produce a hemodynamic flow diversion and to reconstruct laminar flow in the parent artery. The device is a braided mesh cylinder with flared ends composed of 48 nickel-titanium alloy (NiTiNol) and platinum microfilaments. Fully deployed in a target vessel, the FD expands to appose the vessel wall and cover the aneurysm orifice. The porosity is significantly lower than that of conventional intracranial stents. The small



**FIGURE 1.** *The SILK flow diverter.*

diameter of the microfilaments compared with the interstices between each permits enough flow to maintain patency of covered branches and perforators. Given its significant longitudinal flexibility, the SILK has little visible effect on vascular geometry; the hemodynamic effect is provided mainly by the porosity of the device.

Although long-term follow-up data are not yet available, there is accumulating positive experience with FD devices in the treatment of aneurysms that were otherwise difficult to treat or that presented with recurrence after treatment with standard methods.<sup>2-5</sup> We report here our early experience with the SILK FD for the treatment of ruptured, very small aneurysms not amenable to coiling. All 3 patients had failed conventional therapies before presentation.

## PATIENTS AND METHODS

Three female patients presenting after previous acute SAH caused by < 2-mm aneurysm rupture were considered for endovascular treatment with the SILK FD after having failed conventional treatment. The aneurysms were located on the C2 segment of the internal carotid in 2 patients and on the basilar artery bifurcation in 1 patient. As a first step, all patients underwent unsuccessful endovascular treatment with selective coiling or conventional stenting. This attempt was later followed by SILK implantation.

## CASE PRESENTATIONS

### Patient 1

A 57-year-old female patient presented with clinical signs of acute SAH (Hunt and Hess score 1). Computed tomography (CT) demon-

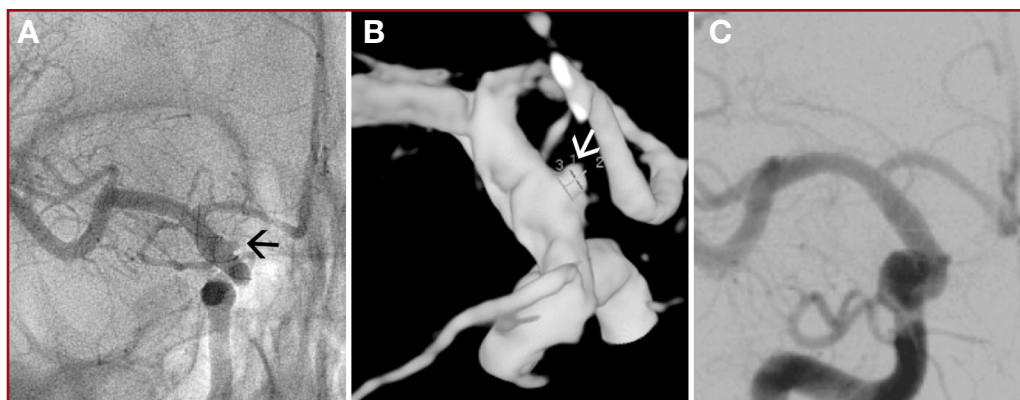
strated significant subarachnoid bleeding (Fisher grade III) and mild ventricular dilatation. Digital subtraction angiography (DSA) with 3-dimensional (3D) reconstruction showed a blisterlike aneurysm on the anteromedial surface of the C2 segment of the right carotid artery. Given the small size and relative broad-based morphology of the aneurysm, coiling was not attempted. Without preloading the patient with antiaggregant medication, a LEO+ stent (BALT Extrusion, Montmorency, France) was placed to cover the lesion site. A concomitant loading dose and systemic perfusion of weight-adjusted tirofiban was started after stent implantation. No immediate effect of stent placement on intraaneurysmal flow was observed. After the procedure, the patient was loaded with 100 mg aspirin and 300 mg clopidogrel, and treatment was continued with 100 mg aspirin and 75 mg clopidogrel daily. Angiographic follow-up performed 2 and 4 weeks after intervention demonstrated no change in aneurysm morphology and no signs of aneurysmal thrombosis. Five weeks after SAH, endoluminal reconstruction of the right internal carotid artery was performed with implantation of an additional SILK FD inside the formerly implanted LEO+, resulting in complete remodeling. The patient recovered well. Clopidogrel treatment was stopped 3 months after SILK implantation. Follow-up brain magnetic resonance (MR) and MR angiography studies performed at 3 months and angiography at 5 months demonstrated signs of reverse remodeling of the carotid artery with complete disappearance of the aneurysm (Figure 2).

### Patient 2

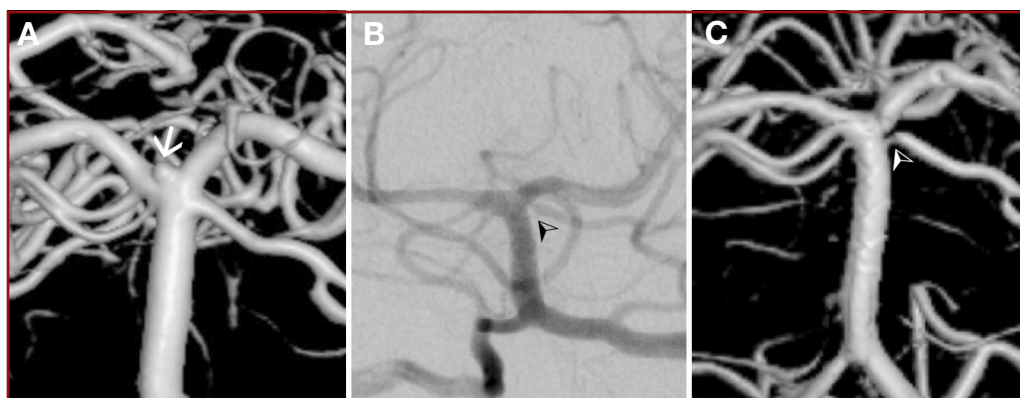
This 65-year-old female patient presented with an SAH proven by CT (Fisher grade IV, Hunt and Hess score 1). Conventional angiography with 3D reconstruction showed a single broad-based aneurysm at the basilar tip of < 2 mm that pointed anterosuperiorly. An attempt at coiling with and without balloon assistance failed. Twenty-four days after the hemorrhage, the patient was prepared for FD treatment. For that purpose, a loading dose of clopidogrel (300 mg) and aspirin (300 mg) was given 6 hours before the intervention. A SILK FD was delivered, extending from the P1 segment of the right posterior cerebral artery to the midbasilar artery. Shortly after uneventful delivery of the device, thrombotic occlusion of the left P1 segment and subsequently of the right distal P1 segment and of both superior cerebellar arteries was noted. An immediate local thrombolysis with local injection of tirofiban led to rapid, complete recanalization of the vessel. The patient left the hospital neurologically intact. Clopidogrel treatment was stopped at 3 months after FD implantation. The 3-month follow-up DSA demonstrated complete occlusion of the aneurysm and patency of related vessels; however, severe stenosis was noted at the origin of the left superior cerebellar artery (Figure 3.)

### Patient 3

This 38-year-old female patient presented with severe headache. Initial brain CT and MR imaging did not show SAH. A lumbar puncture was positive for subarachnoid blood 3 days after the event. CT angiography showed a very small aneurysm on the inferior wall of the C2 segment of the right ICA, also proven by DSA and 3D DSA. Endovascular coil occlusion of the aneurysm was attempted without success. The patient was prepared for FD treatment with a daily dose of 100 mg aspirin and 75 mg clopidogrel, starting 3 days before intervention. Ten days after her SAH, a SILK FD was placed, covering the carotid siphon. After deployment, contrast material stagnation was observed in the aneurysm lumen. Follow-up DSA 10 days after FD implantation demonstrated residual filling of the aneurysm. The patient was discharged without any clinical deficit. The clinical follow-up was uneventful, and clopidogrel treatment was stopped 3 months after implantation. Follow-up DSA at 4 months showed



**FIGURE 2.** Patient 1. Right internal carotid artery (ICA) angiography showing ruptured blisterlike aneurysm (arrows) of the anteromedial wall of the C2 segment of the ICA 3 weeks after LEO+ stent implantation: posteroanterior view (A) and 3-dimensional digital subtraction angiography (B). Follow-up right ICA angiography 5 months after SILK implantation demonstrating complete vessel remodeling (C). In this case, the anterior cerebral, anterior choroideal, and ophthalmic arteries were covered by a LEO+ and a SILK flow diverter and showed uncompromised patency at the 5-month follow-up.



**FIGURE 3.** Patient 2. Three-dimensional (3D) digital subtraction angiography (DSA) reconstruction of the basilar artery showing a tiny ruptured aneurysm at the basilar bifurcation (A). Follow-up DSA (B) and 3D-DSA (C) at 4 months after SILK implantation demonstrating vessel remodeling and lack of aneurysm filling. Note the stenosis at the origin of the left superior cerebellar artery (arrowheads; C).

complete occlusion of the aneurysm, as well as some intimal hyperplasia and stent-related stenosis at the proximal and distal ends of the device (Figure 4).

## DISCUSSION

Flow diversion treatment led to the prevention of SAH recurrence and thrombosis of all 3 aneurysms. Ruptured aneurysms < 2 mm present a considerable challenge for endovascular treatment. These lesions may be blisterlike aneurysms when occurring at the supraclinoid portion of the carotid artery, dissecting aneurysms along the vertebrobasilar system, or true saccular-type aneurysms that can be present at branching points on the circle of Willis. Blisterlike aneurysms (patient 1) often rebleed soon after initial SAH and have poor clinical outcomes if left untreated.<sup>6,7</sup> Because these aneurysms are extremely thin walled, the prompt prevention of recurrent SAH should be the primary goal of treatment.

Moreover, in those small lesions, even recently available coils 1.5 mm in diameter may be inadequate for intrasaccular positioning.<sup>12</sup>

Conventional stenting as a stand-alone treatment has been advocated after promising midterm results in a limited number of cases reported thus far.<sup>1</sup> Because conventional stents often do not affect intraaneurysmal flow, a significant concern for SAH remains, especially with the use of antiplatelet agents. Rebleeding during antiaggregant therapy may lead to death.

The orifice of aneurysms < 2 mm may be smaller than the pore size of conventional intracranial stents. Aneurysm neck coverage by the struts of the stent is therefore unpredictable.

## Flow Diversion Treatment

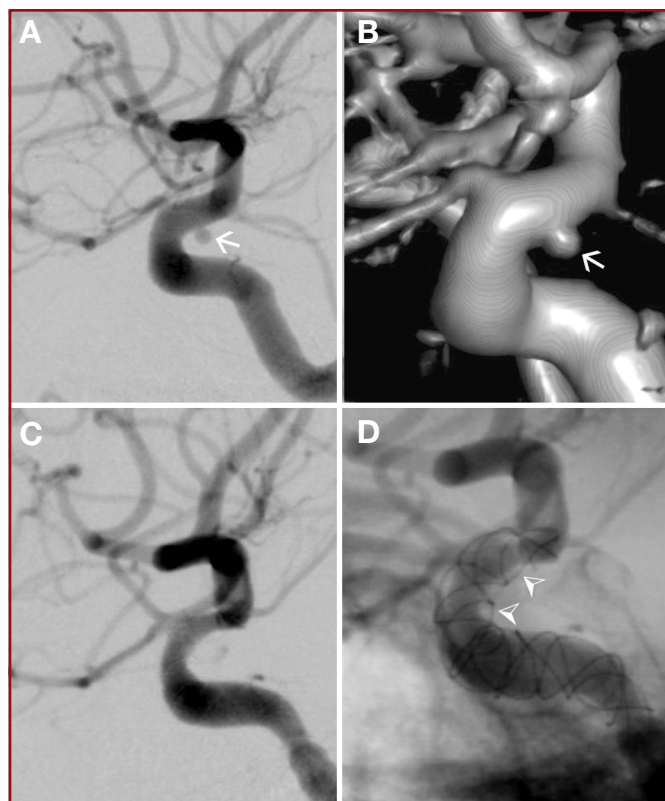
It appears that FDs may provide a more intensive flow diversion than standard stents for very small ruptured aneurysms. These devices are capable of changing the intrasaccular hemodynamics

## Current Therapeutic Options

Occlusion of the parent vessel at the level of the aneurysm is a commonly applied invasive treatment of such aneurysms. This can be achieved either by surgical trapping or by endovascular techniques. Although this approach may provide an immediate and definitive result, it is not feasible for certain locations (basilar trunk, bifurcations) or in cases when collateral circulation is insufficient. Reconstructive treatment with elimination of the aneurysm, by either an open surgical or an endovascular approach, is still controversial and poses significant risks and concerns. The open reconstructive surgery for blisterlike aneurysms is associated with a high rate of rebleeding during preparation and clipping or even after surgical intervention.<sup>8-11</sup>

Traditional endovascular reconstruction has evolved from balloon or stent-assisted coiling for larger aneurysms to the use of conventional stents for lesions considered not coilable.<sup>12</sup> For aneurysms < 2 mm, options are limited. Intrasaccular occlusion attempts are associated with a high risk of rupture, caused mostly by microcatheter manipulation and coil placement.<sup>13</sup>





**FIGURE 4.** Patient 3. Right lateral view (A) of 3-dimensional digital subtraction angiography (DSA) (B) showing a tiny ruptured aneurysm on the inferior wall of the C2 segment of the internal carotid artery. Three-month follow-up DSA (C) and unsubtracted angiography (D) after SILK implantation demonstrating occlusion of the aneurysm and intimal hyperplasia and stenosis of the C2-C3 segments (arrowheads). The ophthalmic artery is not compromised.

responsible for aneurysmal rupture,<sup>14</sup> allowing early prevention of recurrent SAH. Intimal overgrowth over the stent might be an important contributing factor. Endothelial growth along the implant at the level of the neck of such aneurysms may induce significant neck narrowing, causing a significant decrease in intraaneurysmal flow. These factors may contribute to aneurysm thrombosis and vessel wall remodeling. Once remodeling has taken place, the chance of aneurysm recurrence is probably low because of the high mesh density and metallic structure of the embedded FD.

In this small series, treatment was unsuccessfully attempted with coiling in 2 patients and immediate conventional stenting was applied in 1 patient without any visible effect, followed by double-antiplatelet therapy. Patients were closely monitored during their hospital stay and retreated with the SILK FD 3 to 5 weeks after bleeding. SILK implantation provided an immediate aneurysm thrombosis in 1 patient. All 3 patients recovered well without recurrent SAH. Clopidogrel treatment was continued for 3 months after implantation, followed by aspirin therapy alone. During the follow-up period, the aneurysm that was immediately occluded during treatment showed a stable evolution, whereas all

vessels harboring the 3 aneurysms showed complete remodeling at 3 to 5 months with follow-up DSA.

### Advantages and Disadvantages of FD Implantation

The major advantage of the flow diversion treatment is that the aneurysm does not have to be catheterized and there is no need to force endosaccular coiling and associated procedural rupture risks. The implantation of the device may be also technically easier than endosaccular occlusion techniques.

### Antiplatelet Therapy

The most important risk related to FD use in ruptured aneurysms is the need for antiplatelet agents. Recurrent SAH during antiplatelet therapy may be fatal for the patient. The use of antiaggregant therapies in the setting of SAH in general is controversial and not well established. In a retrospective series, Neuroform stent (Boston Scientific/Target, Fremont, California) —assisted coiling was performed for ruptured aneurysms under systemic anticoagulation, and patients were loaded with double-antiplatelet therapy only after intervention. In this series, the rate of thromboembolic and hemorrhagic complications was only 2%.<sup>15</sup> In another similar series, periprocedural intravenous aspirin was given, and clopidogrel loading was started only after the procedure. In this series, thromboembolic and hemorrhagic complications affected 21% of the patients.<sup>16</sup> Regardless of the varying complication rates, the majority of the experience has been related to stent-assisted coiling rather than stenting alone.

After stent implantation, the double-antiplatelet regimen needs to be continued for a long period. Because there is no immediate aneurysm occlusion after stent implantation and because we lack knowledge about the exact aneurysm thrombosis and rebleeding rates for stent-alone treatment, this approach is rightly debated. In our series, the antiplatelet regimen was decided individually and started either several weeks after SAH, when the risk of rerupture was considered to be lower, or, as in the first case, during implantation of a conventional stent with systemic tirofiban therapy. Only 1 patient had immediate occlusion after SILK implantation, but this patient had a conventional stent implantation as a first-step therapy that might have contributed to this result. In the 2 other patients, the aneurysms were occluded at the 3- or 4-month follow up. However, a larger series is needed to establish the actual temporal evolution of occlusion after SILK FD therapy alone.

### Bifurcations and In-Stent Stenosis

FD use may also have 2 important consequences. Although the available evidence seem to be promising in this regard,<sup>2,4,5</sup> covering bifurcations or branching vessels with a low-porosity-profile FD carries the risk of occlusion or embolization of these vessels and may require longer-term double-antiplatelet therapy. The FD may also initiate intimal hyperplasia and luminal stenosis in the covered segment of the parent vessel or branching artery, as was seen in our second and third cases at the 4-month follow-up DSA. The incidence of in-stent stenosis after the application of the Neuroform stent for aneurysm treatment was reported to be 5.1%, with the

majority of cases showing a spontaneous resolution.<sup>17</sup> In the FD series of Lylyk et al,<sup>2</sup> the rate of in-stent stenosis was 18% at 3 months, with 8% of cases showing an improvement already at 6 months. Additional follow-up of our patients with DSA is planned after 1 year following treatment.

Having a new and promising endovascular reconstruction device in the armamentarium of aneurysm treatment does not necessarily mean that this new technology will completely replace the currently existing methodologies, for which more experience and evidence has been accumulated. Larger studies with long-term follow-up are needed to assess the effectiveness and persistence of aneurysm occlusions, the risk of bleeding, and the risk of intimal hyperplasia after treatment.

## CONCLUSIONS

The use of FDs to treat very small “uncoilable” ruptured aneurysms provided complete vessel remodeling in the short term. Although these results may be promising and FDs may provide a solution for this rare cause of SAH, there is still concern related to the risk of recurrent SAH during antiplatelet therapy while remodeling is underway. FDs may provide a treatment option for these aneurysms. An important step forward for stent-assisted treatment of these ruptured aneurysms would be the development of implants that generate less platelet activation and aggregation, thus reducing the current requirement for antiplatelet therapy.

## Disclosure

The authors have no personal financial or institutional interest in any of the drugs, materials, or devices described in this article.

## REFERENCES

1. Fiorella D, Albuquerque FC, Deshmukh VR, et al. Endovascular reconstruction with the Neuroform stent as monotherapy for the treatment of uncoilable intradural pseudoaneurysms. *Neurosurgery*. 2006;59(2):291-300.
2. Lylyk P, Miranda C, Ceratto R, et al. Curative endovascular reconstruction of cerebral aneurysms with the pipeline embolization device: the Buenos Aires experience. *Neurosurgery*. 2009;64(4):632-642.
3. Fiorella D, Kelly ME, Albuquerque FC, Nelson PK. Curative reconstruction of a giant midbasilar trunk aneurysm with the pipeline embolization device. *Neurosurgery*. 2009;64(2):212-217.
4. Fiorella D, Woo HH, Albuquerque FC, Nelson PK. Definitive reconstruction of circumferential, fusiform intracranial aneurysms with the pipeline embolization device. *Neurosurgery*. 2008;62(5):1115-1120.
5. Szikora I, Berentei Z, Kulcsar Z, et al. Treatment of intracranial aneurysms by functional reconstruction of the parent artery: the Budapest experience with the Pipeline embolization device. *AJNR Am J Neuroradiol*. 2010;31(6):1139-1147.
6. Iihara K, Sakai N, Muraio K, et al. Dissecting aneurysms of the vertebral artery: a management strategy. *J Neurosurg*. 2002;97(2):259-267.
7. Ogawa A, Suzuki M, Ogasawara K. Aneurysms at nonbranching sites in the supraclinoid portion of the internal carotid artery: internal carotid artery trunk aneurysms. *Neurosurgery*. 2000;47(3):578-583.
8. Abe M, Tabuchi K, Yokoyama H, Uchino A. Blood blisterlike aneurysms of the internal carotid artery. *J Neurosurg*. 1998;89(3):419-424.
9. Kitanaoka C, Sasaki T, Eguchi T, Teraoka A, Nakane M, Hoya K. Intracranial vertebral artery dissections: clinical, radiological features, and surgical considerations. *Neurosurgery*. 1994;34(4):620-626.
10. Lee JW, Choi HG, Jung JY, Huh SK, Lee KC. Surgical strategies for ruptured blister-like aneurysms arising from the internal carotid artery: a clinical analysis of 18 consecutive patients. *Acta Neurochir (Wien)*. 2009;151(2):125-130.
11. Meling TR, Sorteberg A, Bakke SJ, Slettebo H, Hernesniemi JA, Sorteberg W. Blood blister-like aneurysms of the internal carotid artery trunk causing subarachnoid hemorrhage: treatment and outcome. *J Neurosurg*. 2008;108(4):662-671.
12. Park JH, Park IS, Han DH, et al. Endovascular treatment of blood blister-like aneurysms of the internal carotid artery. *J Neurosurg*. 2007;106(5):812-819.
13. van Rooij WJ, Keeren GJ, Peluso JP, Sluzewski M. Clinical and angiographic results of coiling of 196 very small (< or = 3 mm) intracranial aneurysms. *AJNR Am J Neuroradiol*. 2009;30(4):835-839.
14. Augsburg L, Farhat M, Raymond P, et al. Effect of flow diverter porosity on intraaneurysmal blood flow. *Klin Neuroradiol*. 2009;19(3):204-214.
15. Katsaridis V, Papagiannaki C, Violaris C. Embolization of acutely ruptured and unruptured wide-necked cerebral aneurysms using the Neuroform2 stent without pretreatment with antiplatelets: a single center experience. *AJNR Am J Neuroradiol*. 2006;27(5):1123-1128.
16. Tahtinen OI, Vanninen RL, Manninen HI, et al. Wide-necked intracranial aneurysms: treatment with stent-assisted coil embolization during acute (<72 hours) subarachnoid hemorrhage-experience in 61 consecutive patients. *Radiology*. 2009;253(1):199-208.
17. Fiorella D, Albuquerque FC, Woo H, Rasmussen PA, Masaryk TJ, McDougall CG. Neuroform in-stent stenosis: incidence, natural history, and treatment strategies. *Neurosurgery*. 2006;59(1):34-42.

## Acknowledgment

We gratefully acknowledge the invaluable contribution of John Mangiardi, MD, FASC, to manuscript preparation.