

## Functional evaluation of arteriovenous malformations

**NICHOLAS C. BAMBAKIDIS, M.D., JEFFREY L. SUNSHINE, M.D., PH.D.,  
PETER F. FAULHABER, M.D., ROBER W. TARR, M.D., WARREN R. SELMAN, M.D., AND  
ROBERT A. RATCHESON, M.D.**

*Departments of Radiology and Neurosurgery, Case Western Reserve University School of Medicine, Cleveland; and University Hospitals of Cleveland, Cleveland, Ohio*

Detailed knowledge of the angioarchitecture of arteriovenous malformations (AVMs) is necessary in determining the optimal timing and method of treatment of these challenging lesions. Many techniques are available for studying the functionality of surrounding cortical structures of AVMs. These include the use of positron emission tomography, functional magnetic resonance imaging, magnetoencephalography, and direct provocative testing of cortical function. The use of these methods to determine flow dynamics and tissue perfusion is also reviewed. These techniques are discussed in the present study, and their judicious utilization will enhance the safety of AVM therapy.

**KEY WORDS • arteriovenous malformation • positron emission tomography • flow dynamics**

Defined as abnormal collections of blood vessels characterized by abnormal shunting of blood directly from an arterial supply to venous structures without an intervening capillary bed, AVMs present clinicians with many challenging scenarios given their complex nature and varied locations. Because they can arise in nearly any area of the brain, treatment strategies must take into account both the direct effects of the AVM on surrounding structures as well as the dependence of these structures on its blood supply. Clearly then, measures of the functionality of adjacent neural structures are critical in risk assessment when deciding when and how best to treat these lesions in individual patients.

Although AVMs can cause symptoms due to their epileptogenicity, mass effect, or ischemia, by far the most common presentation of a patient harboring one of these lesions is with an intracranial hemorrhage. A 24-year retrospective analysis of 166 symptomatic patients by Ondra, et al.,<sup>19</sup> who estimated the average risk of major bleeding

to be 4% per year, with a mean interval of 7.7 years between hemorrhages and a morbidity and mortality rate of 2.7% per year. There has also been evidence presented that small AVMs present with hemorrhage more frequently than larger ones, a fact that may be related to higher pressure in the smaller feeding arteries.<sup>1,12,24</sup> In determining the appropriate treatment strategies in an individual patient, clinicians must take into account factors such as the pattern of venous drainage and arterial supply and the presence of critical surrounding neural structures. Although surgical resection continues to be the treatment modality of choice, alternatives such as stereotactic radiosurgery and embolization must be considered. To better estimate surgical risk clinicians can use several methods that aid in the evaluation of local blood flow and cerebral function.

### ANATOMICAL LOCALIZATION

The determination of anatomical location of AVMs primarily depends on MR imaging and MR angiography. Using standard MR imaging methods, critical cortical structures such as the thalamus, internal capsule, and brain stem can be identified and their proximity to the lesion in question can be determined. Flow voids can usually be

---

*Abbreviations used in this paper:* AVM = arteriovenous malformation; CBF = cerebral blood flow; CMRglu = cerebral metabolic glucose; CT = computerized tomography; fMR = functional magnetic resonance; MEG = magnetoencephalography; PET = positron emission tomography.

easily identified, and information can be gained regarding feeding arteries and draining veins. Natural limitations exist when only these methods of localization are used, however, as direct measurements of cortical function are not available. The sensorimotor, language, and visual cortices can only be approximately localized, for example. It is for this reason that concomitant determination of parenchymal function can be of immense value in treatment planning.

## PARENCHYMAL FUNCTION

### *Positron Emission Tomography*

The development of PET scanning has greatly enhanced the ability of clinicians to quantitate accurately both local cerebral function and blood flow. It is the decay of radioactive isotopes that are taken up by metabolically active cells that allows functional localization to become a reality. As the positrons are released from the decaying isotopes, they are annihilated through collisions with electrons, which in turn yield detectable energy.

The ideal radioactive tracer would ostensibly provide quantitative information regarding the metabolic activity of neural tissue as well as its function. In practice these determinations are made indirectly by measuring the utilization of glucose and CBF on a relative scale as functional tasks are undertaken by the patient. These tasks are geared toward stimulating the area of the cortex in question, with a goal of increasing function in those areas so as to create a measurable gradient of activity in the brain. When compared with direct intraoperative cortical mapping, such functional localization has been shown to be accurate.<sup>28</sup>

The metabolism of glucose is indirectly measured through the administration of fluorodeoxyglucose that has been radioactively labeled with fluorine-18. This agent is taken up by cells in metabolically active tissues and it subsequently rapidly decays.<sup>7</sup> Areas with higher local metabolic demand take up more of the tracer, which because of its biochemical composition, is not glycolytically cleaved and remains in the intracellular compartment. Regional areas of CMRglu metabolism are then calculated through arterial sampling. Standardization of PET scanning at individual institutions is mandatory to avoid errors in data acquisition and mathematical calculation. Cerebral blood flow estimations rely on water labeled with radioactive oxygen, and it is the combination of CBF and regional CMRglu metabolism data that provide the best quantitation of cortical neuronal activity. These data can then be used to estimate the proximity of functionally active cortical tissue to AVM location.<sup>16</sup> Areas of cortex that are at risk for ischemia can also be identified using PET scanning, because those areas will demonstrate decreased CBF and relatively preserved regional areas of CMRglu in the face of an increase in the oxygen extraction fraction.<sup>27</sup>

In an effort to fuse both anatomical and functional mapping, PET images can be mapped onto MR images in a complete and accurate way. Anatomical localization can in fact be achieved to such an extent that stereotactic planning can be performed, with errors in the range of 0.32 to 2.22 mm for translations and from 0.32 to 1.70° for rotations.<sup>21</sup> This allows for the maximum benefit of function-

al determination regarding tissue at risk of injury during treatment (Fig. 1).

### *Functional MR Imaging*

Although the value of MR imaging lies foremost in its ability to demonstrate accurately anatomical structures and their relation to one another, since 1992 investigators have attempted to use it in the evaluation of local changes in CBF.<sup>13</sup> Task activation in studied patients results in localized increases in CBF compared with the resting state.

The oxygenated blood in turn is seen as increased signal change on MR imaging sequences with appropriate sensitivity to susceptibility effects of the free electrons on oxyhemoglobin. Such a sequence is run repetitively during the various on and off states of the task. Artifact must be minimized by using motion correction algorithms, and a pixel-by-pixel analysis is performed comparing the task and rest periods.<sup>3</sup> Activation maps can then be constructed with careful attention to motion correction and the presence of large venous structures.<sup>2,31</sup>

Although promising, routine use of fMR imaging as the sole method of functional localization has not been definitively established. Several studies have demonstrated acceptable correlation between fMR imaging and intraoperative mapping. These typically are on the order of 1 cm and have incorporated both sensorimotor and speech area determination.<sup>5,10,32</sup> Maldjian, et al.,<sup>17</sup> reported on the utility of fMR imaging in detecting transposition of language dominance in individuals with left-sided lesions, and sensorimotor function has been demonstrated within the volume of the AVM nidus. Such information alters not only plans for surgical treatment, but also may aid in the placement of boundaries for stereotactic radiosurgery so as to minimize dosages to nearby functional tissue.<sup>8,14</sup> No randomized control studies have been performed, however, and a definitive recommendation regarding the utility of fMR imaging cannot be made.

### *Magnetoencephalography Study*

A noninvasive procedure, MEG utilizes fluxes in the magnetic fields of cortical neurons associated with changes in the electrical current of activated regions. These fluxes must be correlated temporally with motor or sensory stimulation of the cortical regions in question. Limited only by the analog-to-digital conversion rate, this method offers the potential for extremely fine temporal resolution.<sup>23</sup> It has been applied in presurgical determination of distances from cortical lesions to functionally important tissue (Fig. 2). Limitations include the relatively small field of view and the necessity for a shielded room given the low signal-to-noise ratio. A functional risk categorization based on spatial separation has been developed using the precision of this technique.<sup>9</sup> There are fewer false-negative tests than with fMR imaging, and with this technique function deep to the brain surface can be localized.<sup>5</sup>

## PERFUSION MEASUREMENTS

Primary perfusion measurements can provide important information regarding the vascular reserve of tissue in the vicinity of AVMs, which may directly alter treatment

## Functional evaluation of AVMs

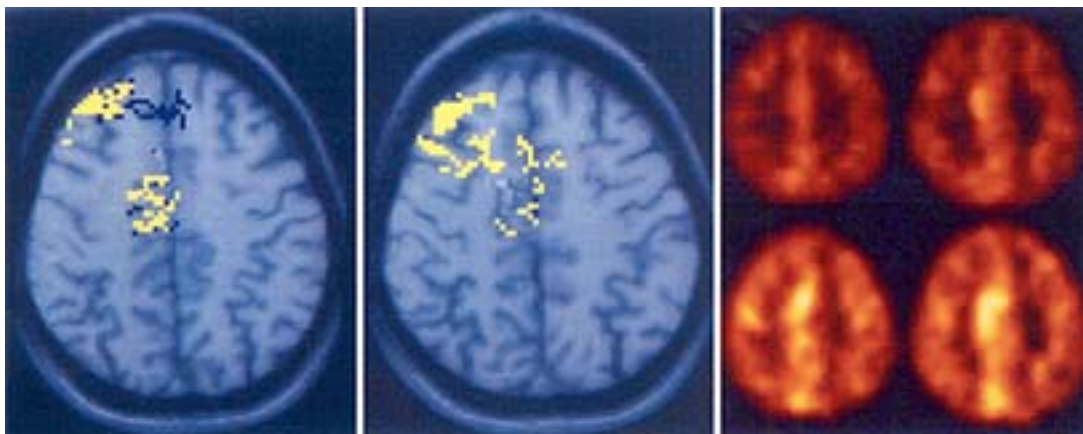


Fig. 1. *Left and Center:* Two  $T_1$ -weighted axial MR images. The second image reveals the nidus as a faint area of increased signal intensity to the right of midline in the frontal lobe. The colored pixels represent areas of activation from left foot motion. *Right:* Four axial fluorodeoxyglucose PET studies revealing increased metabolic activity medially adjacent to the AVM generated by left foot motion. Together these images confirm the close approximation of the nidus to eloquent cortex.

planning. Several methods currently exist to quantify perfusion in a meaningful way. Cold Xe CT scanning in combination with acetazolamide challenge is a very sensitive method that has revealed varying dysfunction in vascular autoregulation (Fig. 3). The majority of patients tested encountered a decreased ability to augment CBF, most often in vascular distributions near the site of the AVM.<sup>26</sup> This lost autoregulation may represent a compromise in hemodynamic reserve or the presence of a “vascular steal” phenomenon. Cold Xe CT scanning is limited by its relative-

ly poor spatial resolution and by the side effects of xenon. Nuclear single-photon emission CT, using the lipophilic tracer hexamethylpropyleneamineoxime, can produce semiquantitative perfusion measures with improved spatial resolution. The best resolution is obtained using PET scanning that allows for multiple scans to be acquired in the same patient given its relatively short scan acquisition time. Tyler, et al.,<sup>27</sup> studied 17 patients and discovered that, although overall CBF increased in the hemisphere ipsilateral to their AVMs, the overall CBF was unaltered while the relative mean transit time of blood through the hemisphere was increased. Acetazolamide may be given to these patients to assess the vascular reserve of tissue adjacent to the AVM, and parameters such as the  $PCO_2$  and/or systemic blood pressure may be altered to provide similar information. Although these perturbations in flow have been documented, their predictive value for outcome or utility in guiding therapy choice has not been validated.

### Evaluation of Flow and Pressure

Analysis of blood pressure and flow in arteries feeding AVMs may reflect the risk of hemorrhage. The mean arterial pressures in the feeding arteries of AVMs in several hundred patients have been obtained and analyzed. Additional characteristics studied included size, location, presence of aneurysms, and pattern of arterial supply and venous drainage. Evidence of high arterial pressure along with deep venous drainage was the most significant indicator of increased risk of future hemorrhage.<sup>4</sup> Elevations of the arterial pressure was found in a cohort of nearly 100 patients to be less profound in the proximity of the nidus, which may produce a regional area of chronic hypoperfusion.<sup>6</sup> Future work in characterizing these areas of AVM angioarchitecture may some day allow estimation of tissue at risk for hemorrhagic complications during treatments.

Estimates of flow velocities are less reliant on invasive techniques than those required to assess pressure. Transcranial Doppler ultrasonography can be used to determine flow velocities even in vessels that may have a normal-

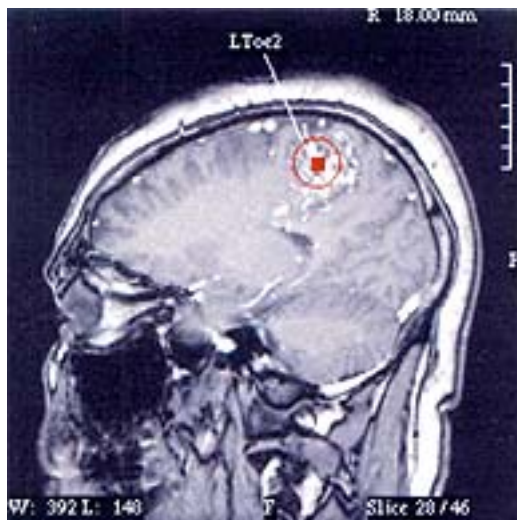


Fig. 2. The MEG image reveals magnetic mapping points superimposed on the patient's  $T_1$ -weighted MR image. The indicated activity was derived from somatosensory stimulation of the left second toe and is marked as a *red square*. The surrounding *circle* represents a statistical confidence volume (closer to the square being greater confidence). The nidus straddles not only the anatomical central sulcus, but also the functionally defined one shown here, centered over the leg region. (Figure contributed by Howard A. Rowley, M.D., University of California San Francisco Medical Center.)

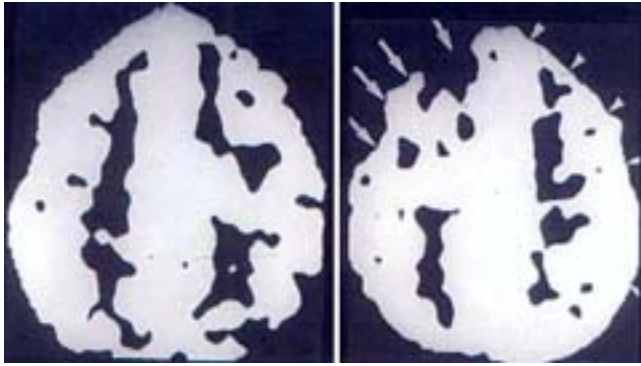


Fig. 3. Images of flow maps from cold Xe CT scanning with areas in white set to reflect flows of at least 30 ml/100 gm/min. The first image was obtained as a baseline. The second was generated following an intravenous Diamox challenge. Note the relative decrease in flow to the right frontal region (arrows), signifying a lack of residual autoregulatory reserve ipsilateral to the known AVM. On the contralateral side there is no decrease, but there is also a lack of increase in the frontal region with challenge compared with the parietal area (arrowheads).

caliber lumen on angiography. Clinical studies have correlated flow measurements to both risk of hemorrhage and progressive neurological deficits. In an analysis of 40 patients with AVMs, Manchola, et al.,<sup>18</sup> found a significant decrease in flow volumes in patients with a history of hemorrhage. These findings were used to promote the hypothesis that surgical ligation of high-flow vessels might incrementally increase the risk of the development of an adverse edematous response in surrounding normal cerebral parenchyma.

Regional changes in blood flow can be significant when one considers the effects of embolization in relation to presurgical planning and the risk of hemorrhage. Large changes in pedicle pressure during embolization have been proposed to predispose patients to periprocedural hemorrhage.<sup>11,30</sup> In fact, Fogarty-Mack and coworkers<sup>6</sup> have shown that AVMs with higher feeding pedicle pressure have a significantly higher natural history risk of hemorrhage. Tarr, et al.,<sup>25</sup> have utilized Xe CT scanning to analyze the local hemodynamic effects of embolization and have found new areas of decreased vascular reserve following AVM embolization. These areas normalized to baseline several weeks following an embolization procedure,<sup>18</sup> suggesting that an appropriate time delay should be taken between embolization stages.

#### Direct Provocative Testing

Direct determinations of testable function corresponding to cortical tissue in a specific vascular distribution can be determined by the infusion of agents such as sodium amytal given intraarterially during provocative testing. This has been performed for many years to localize hemispheric language function<sup>29</sup> and can now be performed with much better specificity by using superselective catheter techniques and ultra-short acting agents such as brevitall or sodium methohexital.<sup>20,22</sup> Areas of displaced parenchymal function can be identified, as Lazar, et al.,<sup>15</sup> demonstrated in patients with far-anterior language function and left hemispheric AVMs. In this way direct pro-

vocative testing of brain tissue in a particular vascular distribution can be performed to minimize risk to its function with treatment.

## CONCLUSIONS

A multitude of technical innovations allow clinicians to analyze AVMs thoroughly, determining not only their anatomical location but also obtaining information regarding vascular flow and pressure dynamics. Such information can tailor the type, extent, and duration of chosen treatment modalities to increase the margin of safety during treatment and decrease periprocedural flow-related hemorrhagic or ischemic complications.

## References

1. Barrow DL, Reisner A: Natural history of intracranial aneurysms and vascular malformations. *Clin Neurosurg* **40**:3–39, 1993
2. Boxerman JL, Bandettini PA, Kwong KK, et al: The intravascular contribution to fMRI signal change: Monte Carlo modeling and diffusion-weighted studies in vivo. *Magn Reson Med* **34**:4–10, 1995
3. Cox RW, Jesmanowicz A, Hyde JS: Real-time functional magnetic resonance imaging. *Magn Reson Med* **33**:230–236, 1995
4. Duong DH, Young WL, Vang MC, et al: Feeding artery pressure and venous drainage pattern are primary determinants of hemorrhage from cerebral arteriovenous malformations. *Stroke* **29**:1167–1176, 1998
5. FitzGerald DB, Cosgrove GR, Ronner S, et al: Location of language in the cortex: a comparison between functional MR imaging and electrocortical stimulation. *AJNR* **18**:1529–1539, 1997
6. Fogarty-Mack P, Pile-Spellman J, Haccin-Bey L, et al: The effect of arteriovenous malformations on the distribution of intracerebral arterial pressures. *AJNR* **17**:1443–1449, 1996
7. Hamacher K, Coenen HH, Stocklin G: Efficient stereospecific synthesis of no-carrier-added 2-[<sup>18</sup>F]-fluoro-2-dioxo-D-glucose using aminopolyether supported nucleophilic substitution. *J Nucl Med* **27**:235–238, 1986
8. Hamilton RJ, Sweeney PJ, Pelizzari CA, et al: Functional imaging in treatment planning of brain lesions. *Int J Radiat Oncol Biol Phys* **37**:181–188, 1997
9. Hund M, Rezai AR, Kronberg E, et al: Magnetoencephalographic mapping: basic of a new functional risk profile in the selection of patients with cortical brain lesions. *Neurosurgery* **40**:936–943, 1997
10. Jack CR Jr, Thompson RM, Butts RK, et al: Sensory motor cortex: correlation of presurgical mapping with functional MR imaging and invasive cortical mapping. *Radiology* **190**:85–92, 1994
11. Jungreis CA, Horton JA, Hecht ST: Blood pressure changes in feeders to cerebral arteriovenous malformations during therapeutic embolization. *AJNR* **10**:575–577, 1989
12. Kondziolka D, McLaughlin MR, Kestle JRW: Simple risk predictions for arteriovenous malformation hemorrhage. *Neurosurgery* **37**:851–855, 1995
13. Kwong KK, Belliveau JW, Chesler DA, et al: Dynamic magnetic resonance imaging of human brain activity during primary sensory stimulation. *Proc Natl Acad Sci USA* **89**:5675–5679, 1992
14. Latchaw RE, Hu X, Ugurbil K, et al: Functional magnetic resonance imaging as a management tool for cerebral arteriovenous malformations. *Neurosurgery* **37**:619–626, 1995
15. Lazar RM, Marshall RS, Pile-Spellman J, et al: Anterior trans-

## Functional evaluation of AVMs

- location of language in patients with left cerebral arteriovenous malformation. **Neurology** **49**:802–808, 1997
16. Leblanc E, Meyer E, Zatorre R, et al: Functional PET scanning in the preoperative assessment of cerebral arteriovenous malformations. **Stereotact Funct Neurosurg** **65**:60–64, 1995
  17. Maldjian J, Atlas SW, Howard RS II, et al: Functional magnetic resonance imaging of regional brain activity in patients with intracerebral arteriovenous malformations before surgical or endovascular therapy. **J Neurosurg** **84**:477–483, 1996
  18. Manchola IF, De Salles AA, Foo TK, et al: Arteriovenous malformation hemodynamics: a transcranial Doppler study. **Neurosurgery** **33**:556–562, 1993
  19. Ondra SL, Troupp H, George ED, et al: The natural history of symptomatic arteriovenous malformations of the brain: 24-year follow-up assessment. **J Neurosurg** **73**:387–391, 1990
  20. Peters KR, Quisling RG, Gilmore R, et al: Intraarterial use of sodium methohexital for provocative testing during brain embolotherapy. **AJNR** **14**:171–174, 1993
  21. Pietrzyk U, Herholz K, Fink G, et al: An interactive technique for three-dimensional image registration: validation for PET, SPECT, MRI and CT brain studies. **J Nucl Med** **35**:2011–2018, 1994
  22. Rauch RA, Viñuela F, Dion J, et al: Preembolization functional evaluation in brain arteriovenous malformations: the superselective Amytal test. **AJNR** **13**:303–308, 1992
  23. Roberts TP, Rowley HA: Mapping of the sensorimotor cortex: functional MR and magnetic source imaging. **AJNR** **18**:871–880, 1997
  24. Spetzler RF, Hargraves RW, McCormick PW, et al: Relationship of perfusion pressure and size to risk of hemorrhage from arteriovenous malformations. **J Neurosurg** **76**:918–923, 1992
  25. Tarr RW, Johnson DW, Horton JA, et al: Impaired cerebral vasoreactivity after embolization of arteriovenous malformations: assessment with serial acetazolamide challenge xenon CT. **AJNR** **12**:417–423, 1991
  26. Tarr RW, Johnson DW, Rutigliano M, et al: Use of acetazolamide-challenge xenon CT in the assessment of cerebral blood flow dynamics in patients with arteriovenous malformations. **AJNR** **11**:441–448, 1990
  27. Tyler JL, Leblanc R, Meyer E, et al: Hemodynamic and metabolic effects of cerebral arteriovenous malformations studied by positron emission tomography. **Stroke** **20**:890–898, 1989
  28. Vinas FC, Zamorano L, Mueller RA, et al: [15O]-water PET and intraoperative brain mapping: a comparison in the localization of eloquent cortex. **Neurol Res** **19**:601–608, 1997
  29. Wada J, Rasmussen T: Intracarotid injection of sodium amyltal for the lateralization of cerebral speech dominance: experimental and clinical observations. **J Neurosurg** **17**:266–282, 1960
  30. Wasserman BA, Lin W, Tarr RW, et al: Cerebral arteriovenous malformations: flow quantitation by means of two-dimensional cardiac-gated phase-contrast MR imaging. **Radiology** **194**:681–686, 1995
  31. Wu DH, Lewin JS, Duerk JL: Inadequacy of motion correction algorithms in functional MRI: role of susceptibility-induced artifacts. **J Magn Reson Imaging** **7**:365–370, 1997
  32. Yetkin FZ, Mueller WM, Morris GL, et al: Functional MR activation correlated with intraoperative cortical mapping. **AJNR** **18**:1311–1315, 1997

Manuscript received October 12, 2001.

Accepted in final form October 25, 2001.

Address reprint requests to: Warren R. Selman, M.D., Department of Neurological Surgery, University Hospitals of Cleveland, 11100 Euclid Avenue, HHS 5042, Cleveland, Ohio 44106. email: wrs@po.cwru.edu.